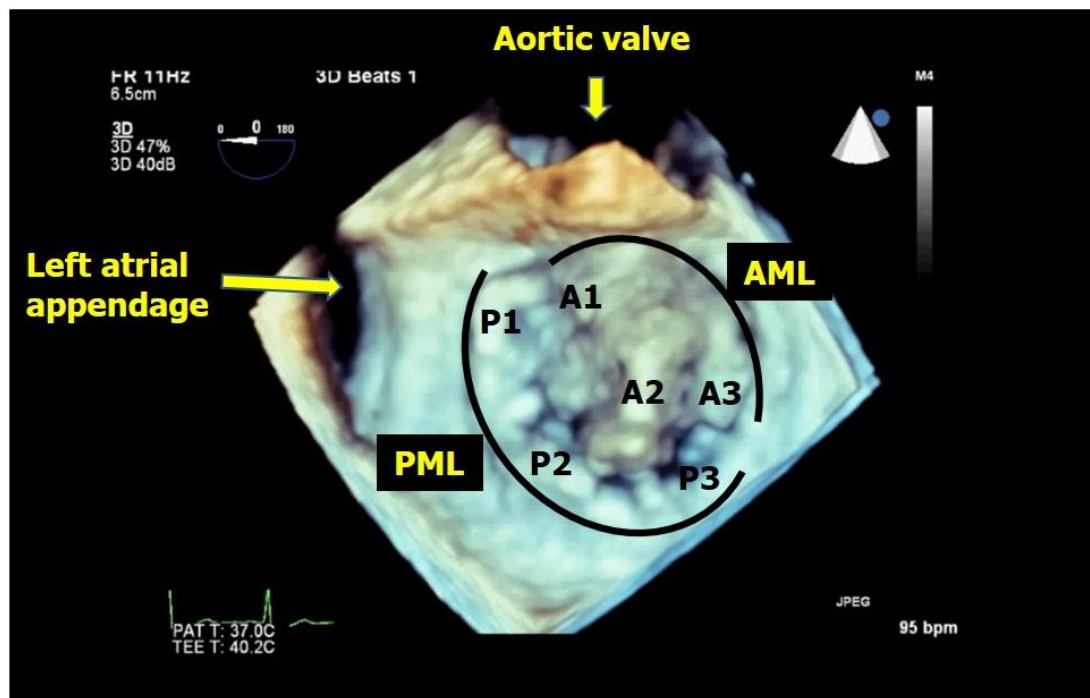


### ANSWER

This is three-dimensional echocardiographic examination of the mitral valve. The mitral valve is being viewed from the left atrial side in this image (Figure below). As you can appreciate, there is marked bulge of the A2 scallop towards left atrium which indicates significant A2 prolapse.



### CORRECT ENTRIES

We received correct responses from the following-

TM-090

Abdul

Rahaman